



Self-Securing Monocanalicular Stent for Treatment of Nasolacrimal Duct Obstruction

Shang-Yi Chiang, Cheng-Jong Chang, Yi-Hao Chen, Le-Tien Lin, and Chiao-Hong Chen*

Department of Ophthalmology, Tri-Service General Hospital, National Defense Medical Center, Taipei, Taiwan, Republic of China

Background: To report the clinical experience and analysis of our results with Ritleng intubation system in patients with congenital and acquired nasolacrimal duct obstruction. **Methods:** Silicone intubation with the Ritleng lacrimal system was performed in 17 patients (20 eyes) from March 2001 to March 2003 to relieve nasolacrimal duct obstruction following the failure of nasolacrimal duct probing. **Results:** The obstruction in 14 of the 20 eyes (70%) was congenital, and 6 of the obstructions (30%) were acquired. The mean period of intubation was 5.2 months (range 4 to 6 months). Silicone intubation was successful in 17 eyes (85%), unsuccessful in 2 eyes (10%), and inadequate in a single eye (5%). Complications were easily treated or were minimal and did not affect the outcome significantly, with the exception of 1 infection. **Conclusions:** Silicone intubation with the Ritleng system is an effective treatment of patients with congenital and acquired nasolacrimal duct obstruction. Self-securing monocanalicular stent is recommended as the procedure of choice after failure of medical therapy and nasolacrimal duct probing.

Key words: nasolacrimal duct obstruction, Ritleng intubation system, self-securing monocanalicular stent, silicone intubation

INTRODUCTION

There have been several favorable reports concerning the use of silicone intubation for alleviating obstructions of the nasolacrimal duct in children and adults¹⁻⁶. In the procedure, the silicone tubing acts as a temporary stent in the obstructed duct, maintaining patency while the tissues around the stent heal. Silicone intubation is a simple procedure, and a variety of instruments and technical modifications have been devised⁶⁻⁸.

Despite the relative ease of the intubation procedure, even experienced surgeons may encounter difficulties, especially in retrieving metal probes from the nose. The Ritleng lacrimal intubation system provides a technique for canicular silicone intubation without the need for the retrieval of metal probes from the inferior meatus⁵.

This article documents our experience with the Ritleng lacrimal intubation system, and serves to illustrate the value and complications attendant with the use of this system.

MATERIALS AND METHODS

Patients

Seventeen patients (representing 20 eyes) with congenital or acquired nasolacrimal duct obstruction were treated using the Ritleng lacrimal intubation system from March 2001 to March 2003 at the Tri-Service General Hospital, Taipei, Taiwan. All patients met the following four criteria: (1) Display sign of epiphoria or lacrimal sac infection, or both; (2) Prior unsuccessful medical treatment (lacrimal sac massage and topical or systemic antibiotics); (3) One or more previous unsuccessful probings of nasolacrimal duct; and (4) Presence of significant residual nasolacrimal duct obstruction that restricted further probing.

Patients with lacrimal drainage system obstructions that involved other than the nasolacrimal duct were excluded from study.

Intubation

Of the 20 intubations performed, 6 were for bilateral nasolacrimal duct obstructions (3 patients) and 14 were for unilateral cases. Fourteen of the 20 obstructions (70%) were congenital and 6 (30%) were acquired.

The Ritleng intubation system (SI-1520, FCI Ophthalmics, Marshfield Hills, MA, USA) consists of a metal probe (Ritleng probe) with a narrow slit that runs the length of the probe from the funnel-shaped entrance to the outlet opening of inferior end (Fig. 1A). The 30-cm-long silicone

Received: February 25, 2004; Revised: April 6, 2004; Accepted: April 16, 2004.

*Corresponding author: Chiao-Hong Chen, Department of Ophthalmology, Tri-Service General Hospital, 325, Cheng-Kung Road Section 2, Taipei 114, Taiwan, Republic of China. Tel: +886-2-87927163; Fax: +886-2-87927164.

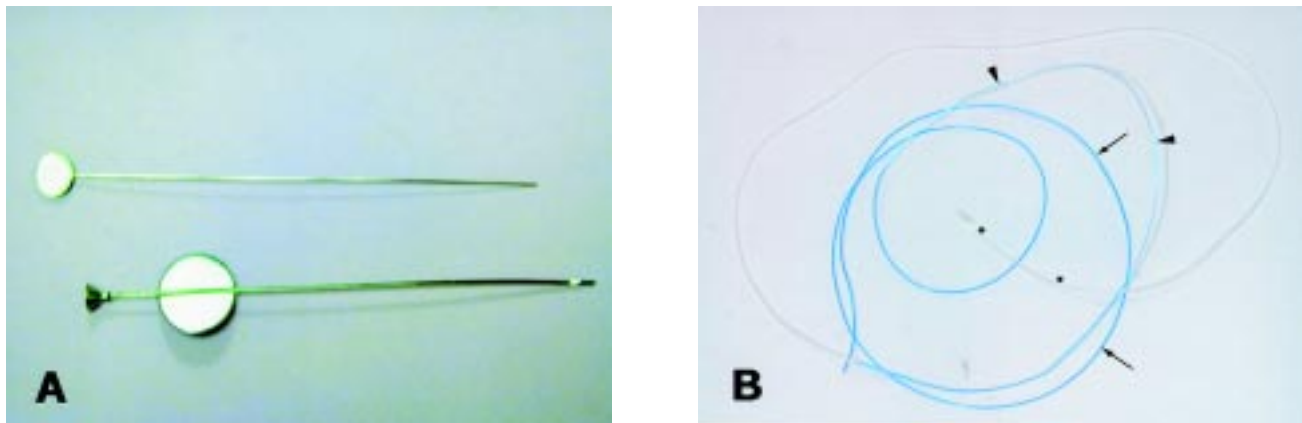


Fig. 1 (A) The Ritleng probe. A funnel-shaped opening on the superior end of the probe facilitates introduction of the Prolene threads. A slit measuring 0.3 mm wide runs the entire length of the hollow probe. (B) The Ritleng intubation set. Two Prolene monofilament threads are composed of a thicker darker blue, 0.4 mm in diameter (arrow head), followed by a thinner light blue portion, 0.2 mm in diameter (arrow), then attached to a 30-cm-long silicone tube (star).

tube is smoothly attached to Prolene monofilament at one end. The Prolene monofilament is composed of a thicker dark blue initial portion followed by a thinner light blue portion so that it can be easily removed from the Ritleng probe. The head of the silicone tube is specially designed to be secured in the punctum without intranasal fixation of the tube (Monka tube) (Fig. 1B).

All procedures were performed under general anesthesia. The punctum was gently dilated. The canaliculus was intubated with Bowman 00 and 0 probe guides to ensure the adequate size of the common canaliculus. The Ritleng probe was passed through the canaliculus into the lacrimal sac, rotated to the upright position, and directed into the nasolacrimal duct (Fig. 2A). The probe was then turned so that the slit faced in the anteromedial direction. The polypropylene thread-guide attached to a silicone tube was introduced into the probe through the proximal funnel-shaped opening (Fig. 2B). If mild resistance was noted, the probe and Prolene were retracted 1 to 2 mm before more of the Prolene was advanced.

As the Prolene exited the probe tip into the nasal cavity, it often curled in the nasal cavity. In most cases, spontaneously emergence from the nose occurred. In 3 cases, Prolene accumulated in the nose, and was retrieved with the use of the Ritleng hook or a small muscle hook. When retrieval of the Prolene was difficult, endonasal forceps under endoscopic visualization was used.

Once the Prolene was removed from the nose, the Ritleng probe was backed out of the nasolacrimal system and separated from the polypropylene thread-guide at its thinner section by sliding the probe out from the lengthwise open slit (Fig. 2C). The thread-guide was pulled out

of the nose, drawing the silicone tubing into the nasolacrimal duct. The tubing was advanced until the end when the fixation head reached the entrance of the punctum (Fig. 2D). The intubated eyelid was then mobilized to ensure that the fixation head did not bury itself inside the canaliculus. At this point, insertion of the fixation head was accomplished by the use of inserter/dilator (Fig. 2E). Finally, the end of the tubing was cut at the nasal fossa with scissors after ensuring that no tension was present in the medial canthus. The tubing hung freely in the nasal cavity, without any need for suture or a knot.

Postoperatively, antibiotic ophthalmic drops and ointment were prescribed for 1 week. All patients' stents were removed in our OPD within 4-6 months, and, in all but 2 patients, stents were removed intact without damage to the canaliculus. In these 2 patients, a stent was displaced either during sleep or daily activity in a child, with the other stent being lost iatrogenically 1 month after the operation.

Criteria for success were defined as complete resolution of previous symptoms and a normal result of dye disappearance test where applicable within 1 week after operation and after stent removal.

RESULTS

We evaluated the intubation technique and the success rate of the Ritleng lacrimal intubation system performed in 17 patients (20 eyes) in our hospital from March 2001 to March 2003. All the patients were successfully intubated. Spontaneous nasal emergence of the Prolene occurred in 15 of the 20 eyes (75%), which simplified retrieval. When the Prolene did not spontaneously emerge from the nose

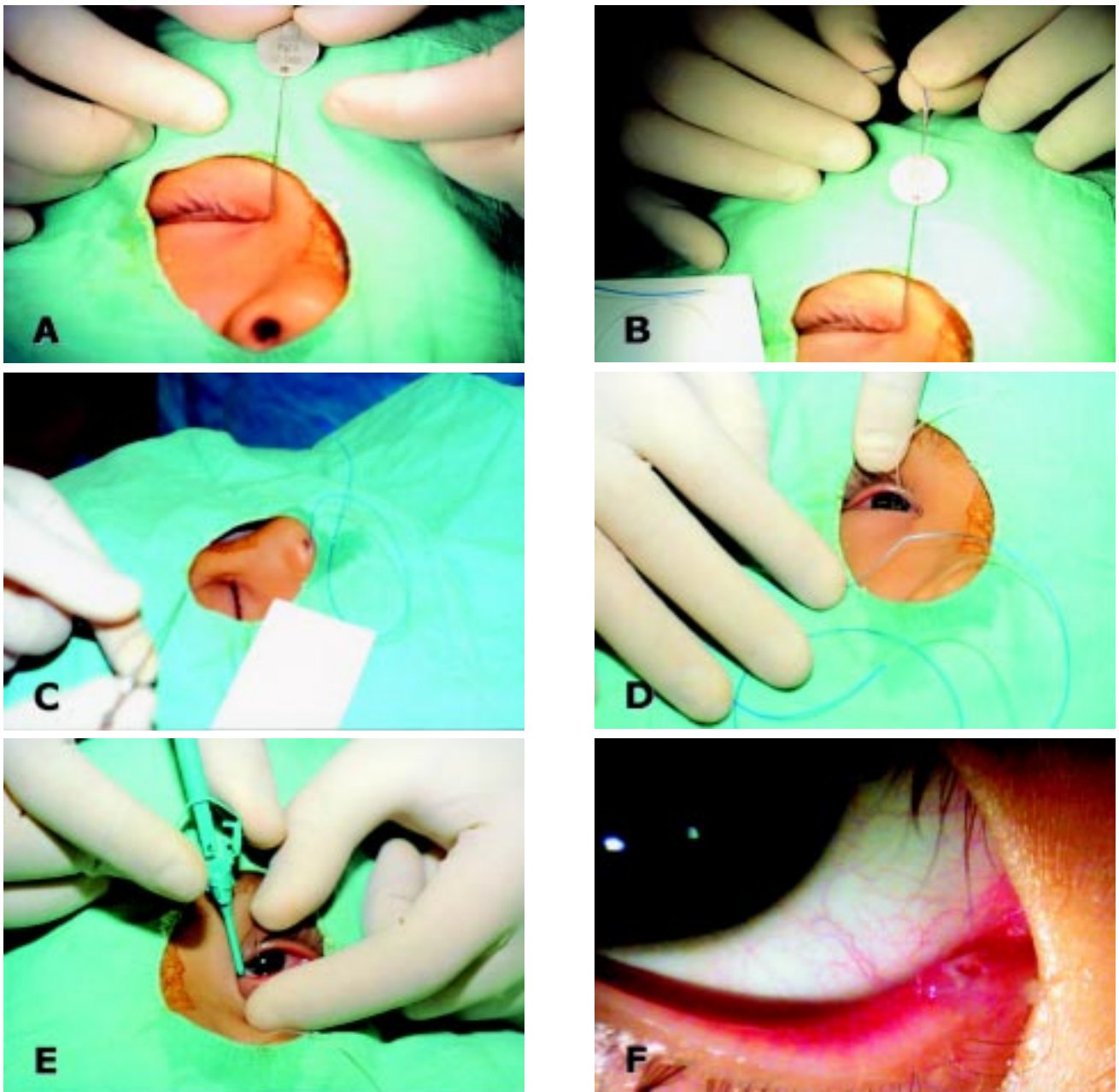


Fig. 2 (A) Lacrimal duct intubation. (B) Retrieval lead guide. (C) Ritleng probe was backed out of the nasolacrimal system and separated from the polypropylene thread-guide. (D) The tubing was advanced until the end of the fixation head reached the punctum. (E) Insertion of the fixation head using the inserter/dilator. (F) Monoka inserted in the lower punctum.

because of serious deformity of nasal turbinater, retrieval was accomplished in 3 eyes (15%) by use of a small muscle hook beneath the inferior turbinate, or by the use of forceps under direct visualization of the inferior meatus in 2 eyes (10%) that require the otorhinolaryngologist to remove Prolene monofilament.

Our success rate of initial silicone intubation in reliev-

ing signs and symptoms of nasolacrimal duct obstruction in this series was 85% (17 eyes out of 20). In the bilateral obstruction cases, there was no discrepancy in the success rate compared to unilateral cases. There were also no differences in the success rates between left and right eyes.

Planned stent removal was performed in 18 of 20 eyes between 4-6 months after surgery (mean duration, 5.2

months). Of the remaining 2 cases, premature lateral displacement requiring unplanned stent removal occurred 2 weeks after surgery in 1 case. The other was due to iatrogenic loss after 1 month. Nasolacrimal duct obstruction eventually resolved in these patients after planned stent removal.

There were no intraoperative or postoperative complications in this study. No ophthalmic injuries occurred from planned or unplanned stent removal in the outpatient office. Also, complications associated with the silicone stent such as punctal erosion, granuloma formation, or corneal erosion, were absent.

DISCUSSION

Silicone intubation is an effective method in treating congenital and acquired nasolacrimal duct obstruction that is nonresponsive to conservative medical treatment and simple nasolacrimal duct probing^{2-4,9}. The stent likely produces nasolacrimal duct patency by maintaining an opening as the edges of the membranous obstruction heal around the stent³. Silicone intubation generally avoids the need for dacryocystorhinostomy, a more advanced operation, in patients with congenital and acquired nasolacrimal duct obstruction. The success rates reported for silicone intubation range from 66% to 100%^{2-6,9-16}. The 85% success rate noted presently is entirely comparable to these previously reported results.

The use of silicone intubation in the treatment of congenital and acquired lacrimal drainage disorders has been described^{2,5,7}. Silicone is soft, relatively inert, and flexible. A variety of intubation sets have been described, generally consisting of a silicone tube bonded or glued to a rigid metal probe⁷. Several types of probes are available, which vary in their malleability and design. Rigid probes facilitate passage through the lacrimal drainage system but may cause injury to the delicate canaliculi and nasal mucosa.

The main difficulty with traditional rigid metal probes lies in the retrieval of the probes from the narrow and obliquely angled inferior meatus. Being nearly vertical, a standard straight lacrimal probe emerging from the ostium will tend to press against the mucosa of the lateral wall, even to the point of dissecting an underlying false passage. Furthermore, attempts to grasp the probe with a hook or hemostat may be difficult, resulting in trauma to the mucosa, bleeding, and lengthy surgery.

The Prolene introduced by the Ritleng system has the advantage of being soft, atraumatic, and more easily retrieved from the nasal cavity. Indeed, the Prolene spontaneously emerges from the nose in most patients. Such was

the case presently, with only 3 cases requiring the probe to be grasped with a small muscle hook¹⁷, and 2 cases of serious deformity of the inferior turbinate that require using of forceps under direct visualization for remove Prolene monofilament.

Presently, the obvious difficulty in intubation or passing the Prolene monofilament in 2 cases may have been a consequence of a persistent obstruction of tear drainage with consequent infection and inflammation leading to scarring, which over time reduced the probability of successful intubation. In all of the failed cases, we encountered difficulty during intubation in passing the Prolene monofilament through the probe, and experienced a tight sensation when pulling Prolene monofilament from the nose. After unsuccessful outcomes, dacryocystography was performed. Severe constriction of NLD was then noted in all these failed cases. The constriction might prevent the Ritleng intubation from relieving the symptoms. When cases were converted to receive DCR operation, satisfactory results were obtained.

The special design of the monocanalicular tube required the integrity of the punctal ring for a secure auto-stable fixation. Iatrogenic punctal rupture or preexistent stricturotomy were contraindicated for this kind of fixation. A suitable diameter of the monocanalicular tube head and its insertion in the upper or lower punctum reduces the displacement rate and foreign body sensation. Additionally, patients' cooperation in minimizing rubbing the eye also is important for a well-positioned tube. Two people in our study experienced tube expulsion due to their tendency to rub their eyes. Instruction to patients and their parents and re-intubation with Ritleng system helped alleviate the symptom of epiphoria.

Complications of the implanted monocanalicular stent has been described either during the operation or when the tubes in place^{2,5,6,16}. Intraoperative complications include lacerated canaliculi and inadvertent false passage. Complications that occur with the tubes in place include expulsion of the Monoka, burying of the fixation head inside the canaliculus, and corneal erosion due to slight entropionning of the punctum¹⁸⁻²². However, in our series we had no major complications.

From our results we conclude that silicone intubation with the Ritleng intubation system is an effective treatment for patients with congenital and acquired nasolacrimal duct obstruction. The monocanalicular stent offers several advantages over other monocanalicular or naso-monocanalicular systems. The fixation head is self-securing, and does not require suture. The procedure takes less time, and the postoperative period is shorter since there are no

stitches to remove. In addition, there is minimal trauma to the nasal mucosa, and the retrieval of the Prolene monofilament leader is easy, even in the hands of relatively inexperienced surgeons. The high success rate obtained with silicone intubation leads us to recommend the procedure in cases of congenital and acquired nasolacrimal duct obstruction in which medical therapy and probing have failed.

REFERENCES

1. Crawford JS. Intubation of obstruction in the lacrimal system. *Can J Ophthalmol* 1977;12:289.
2. Pashby RC, Rathbun JE. Silicone tube intubation of the lacrimal drainage system. *Arch Ophthalmol* 1979; 97:1318-1322.
3. Durso F, Hand SL Jr, Ellis FD, Helveston EM. Silicone intubation in children with nasolacrimal obstruction. *J Pediatr Ophthalmol Strabismus* 1980;17:389-393.
4. Dortzbach RK, France TD, Kushner BJ, Gonnering RS. Silicone intubation for obstruction of the nasolacrimal duct in children. *Am J Ophthalmol* 1982;94:585-590.
5. Pe MR, Langford JD, Linberg JV, Schwartz TL, Sondhi N. Ritleng intubation system for treatment of congenital nasolacrimal duct obstruction. *Arch Ophthalmol* 1998; 116:387-391.
6. Yazici B, Yazici Z, Parlak M. Treatment of nasolacrimal duct obstruction in adult with polyurethane stent. *Am J Ophthalmol* 2001;131:37-43.
7. Crawford JS. Intubation of the lacrimal system. *Ophthalm Plast Reconstr Surg* 1990;18:318.
8. Katowitz JA, Hollsten DA. Silicone intubation of the nasolacrimal drainage system. In: Linberg JV, ed. *Lacrimal Surgery*. New York, NY: Churchill Livingstone Inc, 1988:109-123.
9. Ratliff CD, Mayer DR. Silicone intubation without intranasal fixation for treatment of congenital nasolacrimal duct obstruction. *Am J Ophthalmol* 1994;118: 781-785.
10. Leone CR, Van Gemert JV. The success rate of silicone intubation in congenital lacrimal duct obstruction. *Ophthalmic Surg* 1990;21:90.
11. Milgiori ME, Putterman AM. Silicone intubation for the treatment congenital lacrimal duct obstruction: successful results removing the tubes after six weeks. *Ophthalmology* 1988;95:792-795.
12. Aggarwal RK, Mission GP, Donaldson I, Willshaw HE. The role of nasolacrimal intubation in the management of childhood epiphora. *Eye* 1993;7:760-762.
13. al-Hussain H, Nasr AM. Silastic intubation in congenital nasolacrimal duct obstruction: a study of 129 eyes. *Ophthalm Plast Reconstr Surg* 1993;9:32-37.
14. Song HY, Jin YH, Kim JH. Nonsurgical placement of a nasolacrimal polyurethane stent: long-term effectiveness. *Radiology* 1996;200:759-763.
15. Song HY, Lee DH, Ahn HS. Lacrimal system obstruction treated with lacrimal polyurethane stents: outcome of removal of occluded stent. *Radiology* 1998; 208:689-694.
16. Lee JS, Jung G, Oum BS. Clinical efficacy of the polyurethane stent without fluoroscopic guidance in the treatment of nasolacrimal duct obstruction. *Ophthalmology* 2000;107:1666-1670.
17. Kim HS, Song HY, Kim TH, Kang SG, Kim JH, Yoon HK, Sung KB. Use of a lacrimal stent retrieval hook in the removal of occluded plastic and expandable metallic lacrimal stent. *J Vasc Interv Radiol* 2000;11:762-766.
18. Kaufman LM, Guay-Bhatia LA. Monocanalicular intubation with Monoka tube for the treatment of congenital nasolacrimal duct obstruction. *Ophthalmology* 1998;105:336-341.
19. Rauz S. Monocanalicular nasolacrimal duct intubation [letter]. *Ophthalmology* 1998;105:1794.
20. Glatt HJ. Monocanalicular nasolacrimal duct intubation [letter]. *Ophthalmology* 1998;105:1794-1795.
21. Fayet B, Assouline M, Bernard JA. Monocanalicular nasolacrimal duct intubation [letter]. *Ophthalmology* 1998;105:1795-1796.
22. Fayet B, Bernard JA, Assouline M. Bicanalicular versus monocanalicular silicone intubation for nasolacrimal duct impatency in children. *Orbit* 1993;12:149-156.

